

International Journal of Clinical Obstetrics and Gynaecology

ISSN (P): 2522-6614
ISSN (E): 2522-6622
© Gynaecology Journal
www.gynaecologyjournal.com
2018; 2(1): 16-19
Received: 06-11-2017
Accepted: 07-12-2017

Dr. Poonam Khicher
3rd Year Resident, Department of
OBGY, SMS Medical College,
Jaipur, Rajasthan, India

Dr. Oby Nagar
Professor and Unit Head,
Department of OBGY, SMS
Medical College, Jaipur,
Rajasthan, India

Dr. Lata Rajoria
Professor and Head of
Department, Department of
OBGY, SMS Medical College,
Jaipur, Rajasthan, India

Correspondence

Dr. Poonam Khicher
3rd Year Resident, Department of
OBGY, SMS Medical College,
Jaipur, Rajasthan, India

A comparative interventional study of single port and double port methods in diagnostic laparoscopy for evaluation of cases of infertility in department of obstetrics and gynaecology, SMS medical college & hospital, Jaipur

Dr. Poonam Khicher, Dr. Oby Nagar and Dr. Lata Rajoria

Abstract

Introduction: Infertility is defined as incapability of a couple to achieve conception after a year of unprotected intercourse. Diagnostic laparoscopy is gold standard technique for evaluating such cases. The view obtained at laparoscopy is better than at the time of laparotomy. This is called "Panoramic view". Introducing only one port for entry of camera *vis a vis* one extra ancillary port for diagnostic purpose for manipulating abdomino-pelvic structures has been recommended by several authors but authentic studies are lacking

Aims and Objectives: To compare single puncture with double puncture diagnostic laparoscopic technique and to evaluate benefits and side effects of a second puncture in infertile women.

Materials and Methods: This study was a hospital based comparative type of interventional study conducted in the Department of Obstetrics & Gynaecology, S.M.S. Medical College, Jaipur from March 2016 to July 2017. All infertile women (both primary and secondary) admitted and posted for diagnostic laparoscopy by single and double puncture method in, of age between 20-40 years were enrolled in the study.

Results: In majority of patients (80%) by single port, there was incomplete visualisation of both fallopian tubes, ovaries, pouch of douglas, spill of dyes. Full length of both tubes till fimbrial end, complete evaluation of both ovaries and their pathology was not possible even with proper technique, bowel preparation and Trendelenburg position. Using second port, it was possible to evaluate complete pelvic structures and their pathologies, bilateral or unilateral spill of dye, pouch of douglas by manipulation of intestinal loops and holding the tubes.

Conclusion: Approximately in 90% of the patients the operative surgeon could make out pathology and get a proper look at the structures along with therapeutic correction of pathologies in same setting without causing extra discomfort and postoperative pain and complication in comparison with single port technique.

Keywords: Infertility, diagnostic laparoscopy, double port, single port, pouch of douglas

Introduction

Infertility is well-defined as failure to conceive during one year of unprotected intercourse^[1]. Leading causes of infertility include tubal disease, ovulatory disorders, uterine or cervical factors, endometriosis and male factor infertility. The female factor contributes most (i.e. 40-45%) to etiology of infertility followed by male factor (32-40%), both partners (10%) and unexplained (10%)^[2]. In many cases the exact cause of infertility may not be elucidated, whether it is the tubal factor, male factor, uterine factor, or a combination. This adds to the emotional trauma of the couple. It has been estimated that using diagnostic laparoscopy as a standard tool would reduce the apparent incidence of unexplained infertility from 10% to 3.5%^[3].

Diagnostic laparoscopy is the gold standard in determining the cause of infertility and is also frequently performed as a standard procedure^[4]. The view obtained at laparoscopy is better than at the time of laparotomy. This is called "Panoramic view". Introducing only one port for entry of camera *vis a vis* one extra ancillary port for introducing a simple Maryland forceps for manipulating abdomino-pelvic structures has been recommended by several authors. While doing Diagnostic laparoscopy by single port technique, which is most commonly used method in all the infertility clinics, it is observed that there is incomplete visualization of pelvic organs.

Full length of both tubes till fimbrial ends and complete visualization of both ovaries and pouch of Douglas is not possible due to bowel loops, adhesions, any cysts, fibroids or any pelvic mass. By putting second port, it is possible to manipulate bowel loops, holding up the tubes, separating the flimsy adhesions by ancillary instruments like grasper, Maryland forceps, bowel grasper, dissecting forceps. Overall, by putting second port in diagnostic laparoscopy as a routine, results and final diagnosis of infertility will be improved because of further more exploration of pelvic organs.

Material and Methods

Study Design

This study is a hospital based comparative type of interventional study conducted in the Department of Obstetrics & Gynaecology, S.M.S. Medical College, Jaipur from March 2016 to July 2017.

Study Participants

A total no of 100 infertile women (both primary and secondary) admitted and posted for diagnostic laparoscopy in department of Obstetrics and Gynaecology, SMS Medical College, of age ranging between 20-40 years were enrolled in the study.

Study Method

After thorough gynaecological examination and with all necessary investigations (human semen analysis, baseline endocrinal investigations, post coital study, cervical mucus study, ovulation study, post menstrual HSG) patients are admitted a day before surgery.

Written consent form is taken from all the patients.

Diagnostic laparoscopy was performed in 50 patient by only putting one port and only laparoscope used for visualization of pelvic organs with the help of trendelenberg’s position and uterine manipulation .50 patients were evaluated by putting second port for ancillary instruments like Maryland forceps for bowel mobilization and holding of fallopian tubes. Finding of both groups were collected, analysed and compared.

Observations and Results

Since not much work has been done to compare the diagnostic efficacy of single port method and double port method in diagnostic laparoscopy which is still prevalent at many centres, in evaluation of infertile patient, we decided to undertake this study.

Demographic data	Single port	Double port
Mean age (years)	26.18	24.7
BMI (Kg/m ²)	26.1	24.7
Active married life (years)	4.53	4.29
Primary infertility	33	39
Secondary infertility	11	17

In our study, mean age of the subjects in single port study group is 26.18 years and in double port study group is 24.74 years. 46% study subjects were from rural area and 54% were from urban area. Most of the study subjects (94%) were non working (housewives). 38% of study subjects were belonged to lower socio economic class and 56% were belonged to lower middle class. Mean BMI in both groups ranges between 24.7-26.1. Duration of active married life was 4.2 yrs to 4.5 yrs (mean) in both groups. 72% of study subjects were of primary infertility and 28% of study subjects were secondary infertility. Both groups were comparable in all demographic areas.

There was a significant difference was found in visualization of pelvic organs by single port and double port method.

In single port method, only one port is used for laparoscope insertion. Pelvic organs are visualized by uterine manipulation by uterine manipulator and Trendelenburg’s position. While in double port method, another port (5 mm) is created under vision and ancillary instruments like Maryland forceps introduced and used for manipulation of fallopian tubes and loops of intestine.

It is found that during procedure anterior surface of uterus was seen in all cases of both single port group and double port group. This finding was not statistically different in both of the study groups as it is dependent upon the adequate anteversion of uterus done with the help of uterine manipulator.

It is found that in Single port group pouch of Douglas seen completely only in 14% of cases and not seen completely in 86% of cases and in double port group pouch of Douglas seen in almost all (96%) cases. Only in 4% of cases in double port pouch of Douglas was not seen completely.

Due to adhesions and intestinal loops, proper visualization of pouch of Douglas is difficult. In double port method, manipulation of intestine and removal of adhesions is possible due to other instruments.

Structures visualized by single port and double port

Structures visualised	Single port (50)	Double port (50)
Anterior surface of uterus	50 (100%)	50 (100%)
Pouch of DOUGLAS	7 (14%)	48 (96%)
B/L Tubes	2 (4%)	49 (98%)
B/L Ovaries	4 (8%)	49 (98%)
Spill of dye	17 (34%)	17 (34%)
Spill of dye from fimbrial ends	2 (11%)	14 (82%)
Final diagnosis	2 (4%)	48 (96%)

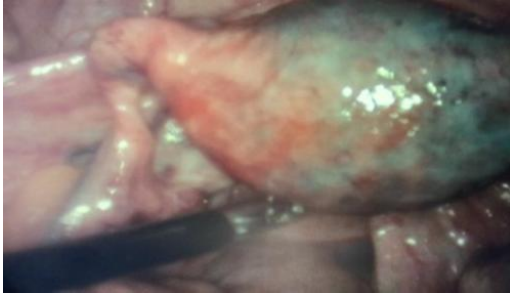
It is observed that complete visualization of right and left fallopian tube during procedure was found in almost all cases of double port 98% and 96% respectively. Whereas only in 4% cases in single port group right and left fallopian tube seen completely and rest in 96% cases right and left tubes not seen completely. In higher number of cases right and left tubes seen completely in double port group as compared with single port group. In double port method, by holding the fallopian tube with non-traumatic Maryland forceps, we were able to see complete length of fallopian tubes till the fimbrial ends And any focal dilatation of tubes, any alteration in tubo-ovarian relation by peri-tubal adhesions, and adenexal masses. In majority of cases loops of intestine were covering the full length of fallopian tubes. So, complete visualization was not possible without holding the tubes with Maryland forceps or manipulation of intestine. It was also observed that during chromo perturbation dye test, if there is spill of dye seen in pouch of Douglas, we were not able to comment on both tubal patency in single port, without seeing spill of dye from fimbrial end of both side of tubes.

Comparison of Study groups in relation to spill of Dye seen from fimbrial ends of tubes in both groups

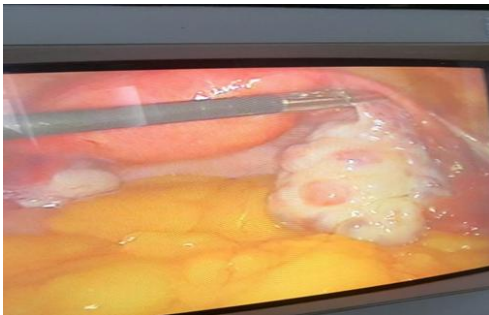Spill of Dye seen from ends	Single port		Double port	
	N	%	N	%
seen	2	11.76%	14	82.35%
not seen	15	88.23%	3	17.64%
Total	17	100	17	100

It is possible to see spill of dye in pouch of Douglas in unilateral tubal block, which could not be diagnosed by single port method. In double port method, spill of dye from fimbrial end was seen after holding the fallopian tubes one by one and unilateral fimbrial block, bilateral fimbrial block, unilateral cornual block, extravasation of dye, all these finding were possible to in double port method.

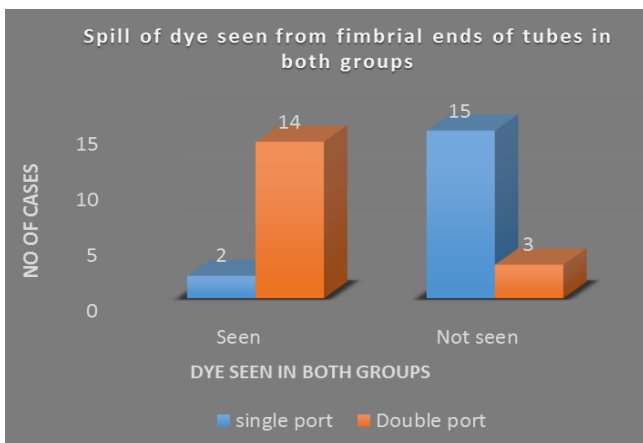
Extravasation of dye in cornual block



It is observed that complete visualization of right and left ovaries during procedure was found in almost all cases of double port (98%). Whereas only in 4% cases in single port group right and left ovary seen completely and rest in 96% cases right and left ovaries not seen completely. So in majority of cases with single port, ovarian pathologies like simple cysts, chocolate cysts, multiple follicular cysts in PCOD were missed due to incomplete visualization. While in double port method, manipulation of tubes and gut is possible, so a proper evaluation of all ovarian pathologies was possible.



It was observed that that spill of dye present in 34% of total study subjects and no spill of dye seen in 66% of total infertility cases (blocked tubes). In single port cases, when dye was present, commenting on unilateral spill or bilateral spill was not possible. In Double port cases, comment on unilateral/bilateral block could be done in presence of spill of dye.



There was no significant difference found in both groups in relation of operating time. So putting an extra port without increasing operative time and increasing diagnostic efficacy will improve overall diagnostic power of the test.

In the present study in relation to ease of surgeon during procedure, there was no significant difference found in both the groups.

In this study postoperative pain (6 hour VAS score) no significant difference was found in between the two study groups. It is observed that final diagnosis could be made only 4% cases in single port group and in almost all cases (96%) in double port group. There were high number of cases in which cause of infertility was diagnosed in double port group as compare with single port.

By above discussion, our study showed that double port method in Diagnostic Laparoscopy is more reliable method to evaluate the pelvic pathologies. By putting one extra port, diagnostic efficacy was increased significantly, without increasing cost and surgeon and patient’s discomfort. So our study recommends that Diagnostic laparoscopy in evaluation of infertile patients should be done by double port method routinely.

Discussion

Many authors recommended that diagnostic laparoscopy in infertility should always done by double port methods but authentic studies are lacking. There are no comparative studies ever done to compare single port and double port method in our knowledge and no authentic data is available in literature. Although in few study’s authors mentioned that double puncture method is more reliable in making proper diagnosis.

In a retrospective study done by Chong AP, Elligers K *et al.* [5] confirms that laparoscopy should be performed early in the infertility investigation when pelvic pathology is suspected. If performed, the procedure should be via the double-puncture technique. Otherwise, it should be done when the rest of the tests have proven to be within normal limits and there is only the possibility of peritoneal involvement (i.e., pelvic adhesions or pelvic endometriosis). Our impression is that the single-puncture technique seriously compromises the physician's ability to assess pelvic pathology adequately [5].

An another study done in Gujrat, India by Divyesh N. Panchal *et al.*, author also agreed that double puncture method is more reliable to rule out pelvic pathologies [6].

So we decided to conduct a comparative study in diagnostic laparoscopy in infertility cases using single port and double port. In our study most of the study subject in single port group (mean age-26.18±4.4) and in double port group (mean age-24.74±3.6) belonged to 21-30 years of age group, is similar to result found in another study done by Divyesh N. Panchal *et al.* [6].

A study conducted by Talat Naz *et al* (7) also found similar result that majority of patient (136) were belonged to 21-30 years of age group. In our study BMI among the study subject is average 26.18±4.4 kg/m² single port group and 24.74±3.65kg/m² in double port group. Similar range of BMI in infertile patients were found in study done by Nivedita Goverdhan *et al.* [8] In our present, mean active married life duration was 4.53±2.4 years in single port and 4.29±2.16 years in double port, both are comparable. Similar results were found in many other studies. It was 5.6 years in study done by Pallavi Agrawal *et al.* [9]. It was found that in our present study there was 72% patients were of primary infertility and 28% patients were of secondary infertility in both groups. Similar results were found in study done by Divyesh N. Panchal *et al.* [6] which were around 70% patients of primary infertility and 30% patients were of secondary

infertility. Another study done in Osaka, Japan by Isao Tsuji, Kazumi Ami *et al.* [10] found 73.7% patients were of primary infertility and 26.3% were of secondary infertility. These findings are consistent with the mean age group of participants. It was observed that that spill of dye present in 34% of total study subjects and no spill of dye seen in 66% of total infertility cases (blocked tubes). Tubal blockage is found to be most common cause of infertility in India i.e. 42%. [11] The results of this study were similar to Raida M *et al.* [12] which stated tubal factor was responsible for 16.53% of primary and 39.09% of secondary infertility with most cases were diagnosed to have bilateral tubal block. Otolorin EO *et al.* [13] in their study found tubal block in 44.95% of cases of which unilateral block in 6.6% and bilateral block in 35.5% cases.

Conclusion

Our study was comparative study between single port and double port method in Diagnostic Laparoscopy in infertile patients. Results of our study showed that in comparison to single port method, evaluation of infertile cases by double port has much higher yield in identifying complete length of fallopian tubes till fimbrial ends, complete evaluation of ovarian pathologies, accurate results of chromo perturbation test, and complete visualization of pouch of Douglas and other pelvic pathologies. So overall efficacy of diagnostic laparoscopy was improved by double port method without any extra financial, physical burden to the subjects in similar time frame.

So, hereby we conclude that diagnostic double port laparoscopy is an easy, cost effective, highly accurate method of evaluation of infertile cases. We also invite further studies into this subject with special implementation of combined diagnostic as well as therapeutic uses of double port diagnostic laparoscopy in evaluation and management of upcoming epidemic of infertility.

References

1. Hammond MG. Evaluation of the infertile couple. *Obstet Gynecol Clin Nor.*
2. Padubidri VG, Shirish DN. The Pathology of conception. In: Shaw's Text book of Gynaecology. 12th ed. New Delhi: BI Churchill Livingstone. 154-68th Am. 1983, 1987; 14:821-30.
3. Drake T, Tredway D, Buchanan G, Takaki N, Daane T. Unexplained infertility. A reappraisal. *Obstet Gynecol.* 1977; 50:644-6.
4. Bosteels J, Van Herendael B, Weyers S, D'Hooghe T. The position of diagnostic laparoscopy in current fertility practice. *Hum Reprod Update.* 2007; 13:477-85.
5. Chong AP, Elligers K. Usefulness of double-puncture laparoscopy in the infertility work-up. *Int J Fertil.* 1987; 32(1):38-40.
6. Panchal DN, Shah A. Role of diagnostic laparoscopy in infertility, *Int J Reprod Contracept Obstet Gynecol.* 2016; 5(12):4180-4183.
7. Naz T, Hassan L, Gulmeen, Nighat F, Shahida Sultana S. Laparoscopic Evaluation in Infertility, *Journal of the College of Physicians and Surgeons Pakistan.* 2009; 19(11):704-707.
8. Goverdhan N, Wankhede S, Thakare S, Shahane S, Evaluation of cases of infertility by diagnostic laparoscopy, *Int J Reprod Contracept Obstet Gynecol.* 2017; 6(3):924-929.
9. Agrawal P, Bhandari S, Singh A, Ganguli I. Findings in diagnostic laparoscopy in patients with unexplained infertility; *Fertil Sci Res.* 2015; 2:29-33.

10. Tsuji I, Ami K, Miyazaki A, Hujinami N, Hoshiai H. Benefit of Diagnostic Laparoscopy for patients with unexplained infertility and normal Hysterosalpingography finding, *Tohoku J Exp Med.* 2009; 214:39-42.
11. Kanal P, Sharma S. Study of primary infertility in females by diagnostic laparoscopy. *Internet J Med Update.* 2006; 1(2):7-9.
12. Raida M, Al-Wazzan, Entessar A. Diagnostic laparoscopy in female infertility. *Ann Coll Med.* 2009; 35(1):58.
13. Otolorin EO, Ojengbede O, Falase AO. Laparoscopic evaluation of the tuboperitoneal factor in infertile Nigerian women. *Int J Gynaecol Obstet.* 1987; 25(1):47-52. 64.