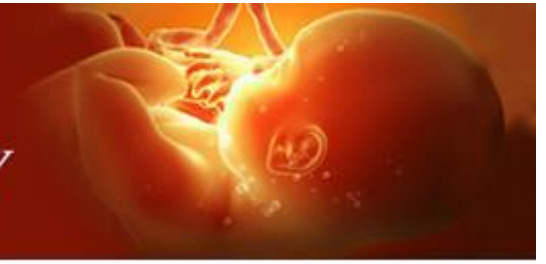

International Journal of Clinical Obstetrics and Gynaecology



ISSN (P): 2522-6614
ISSN (E): 2522-6622
© Gynaecology Journal
www.gynaecologyjournal.com
2020; 4(3): 144-147
Received: 10-03-2020
Accepted: 14-04-2020

Dr. Daksha Bhohe
Specialty trainee, Obstetrics &
Gynaecology Department,
Rotherham General Hospital,
Moorgate Road, Rotherham S60
2UD, United Kingdom

Radwan Faraj
Consultant, Obstetrics &
Gynaecology Department,
Rotherham General Hospital,
Moorgate Rd, Rotherham S60
2UD, United Kingdom

Laparoscopy in ectopic pregnancy: Diagnostic or therapeutic tool?? Review of 3 cases

Dr. Daksha Bhohe and Radwan Faraj

DOI: <https://doi.org/10.33545/gynae.2020.v4.i3c.594>

Abstract

Ectopic pregnancy is a common condition in early pregnancy managed laparoscopically if needs surgical management. Most of the ectopic pregnancies can be diagnosed prior to laparoscopy. Transvaginal scan has become a gold standard in the diagnosis. Diagnosis however depends on the skill and experience of the sonographer. A clinician with no experience in scanning would depend on the scan report and clinical presentation of patient. Would it be acceptable to carry out a laparoscopy for diagnostic purpose rather than therapeutic in the diagnosis of ectopic pregnancy? We reviewed 3 cases of suspected ectopic pregnancy in our department where a laparoscopy was carried out with normal findings. This review looks at the scan findings, clinical presentation, biochemical markers of each patient to see if laparoscopy could have been avoided in each of these cases and a more conservative approach could have been taken.

Keywords: Ectopic pregnancy, laparoscopy, surgical, transvaginal scan, pregnancy of unknown location

Introduction

An ectopic pregnancy is any pregnancy implanted outside of the endometrial cavity. In the UK, the incidence is approximately 11/1000 pregnancies, with an estimated 11 000 ectopic pregnancies diagnosed each year. The incidence of ectopic pregnancy in women attending early pregnancy units is 2–3% ^[1]. Unfortunately, women still die from ectopic pregnancy, with 5 maternal deaths reported in the recent MBRRACE report 2015-17 ^[2].

Though, the case fatality rate has decreased over recent years, suggesting that earlier diagnosis and treatment may have made an impact, diagnosis can still be challenging.

A good history with knowledge of associated risk factors, clinical examination and outcomes of investigations like serial levels of β -hCG (human chorionic gonadotropin hormone), progesterone, full blood count trends and ultrasound are useful to come to a diagnosis and decide on further management. Management of ectopic pregnancies can be expectant, medical or surgical. Laparoscopy is the preferred surgical option with less hospital stay and faster recovery and is usually performed with therapeutic intention. Laparoscopic salpingectomy and salpingostomy are known procedures to treat tubal ectopic pregnancies. With transvaginal scanning considered as the gold standard, are we justified in carrying out a laparoscopy only for diagnosis of ectopic pregnancy? With this view, we reviewed 3 cases of suspected ectopic pregnancy in our department where laparoscopic findings were normal raising a thought whether the procedure was indicated in each case.

Case 1

A, 21 year old, Para 1 with previous 1 vaginal delivery attended at 6 weeks with pain in left iliac fossa and minimal PV bleeding in the middle of the night. On examination, she had tenderness in left iliac fossa. Her biochemical markers showed a β -hCG level of 232 IU/L and progesterone level of 60.4 nmol/L. A bedside USG performed by an experienced doctor showed a possible pseudosac in the uterus and a 34x16.7 mm mass medial to left ovary with normal right ovary. Moderate amount of free fluid was seen in pouch of Douglas with no evidence of fluid in the hepatorenal angle. Since, she was stable with a haemoglobin level of 13.6g/L, she was kept nil by mouth for laparoscopy and salpingectomy in the morning. However, patient declined surgery and was concerned about ongoing pregnancy and wished to have a repeat β -hCG level. A departmental scan (Figure1) performed in the morning showed similar findings raising suspicion of ruptured ectopic.

Corresponding Author:
Dr. Daksha Bhohe
Specialty trainee, Obstetrics &
Gynaecology Department,
Rotherham General Hospital,
Moorgate Road, Rotherham S60
2UD, United Kingdom

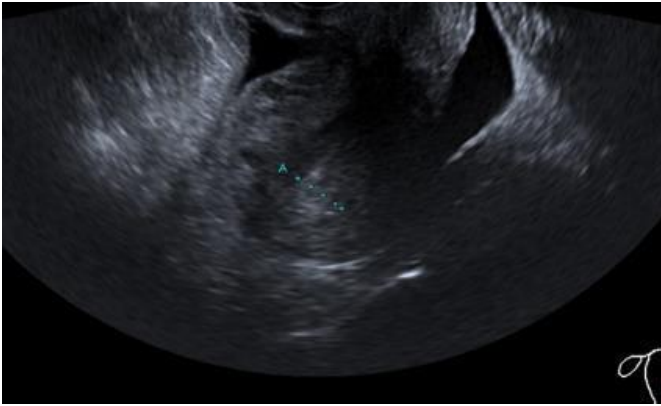


Fig 1: Free fluid in Pouch of Douglas

After further counselling, patient agreed for laparoscopy. Laparoscopy showed normal uterus and ovaries with no evidence of ectopic pregnancy and minimal amount of free fluid. Uterine manipulation was avoided during the procedure. Repeat β -hCG performed in 48 hours showed doubling in the level with a value of 594 IU/L. Further scan performed a week later showed evidence of intrauterine pregnancy (Figure 2).

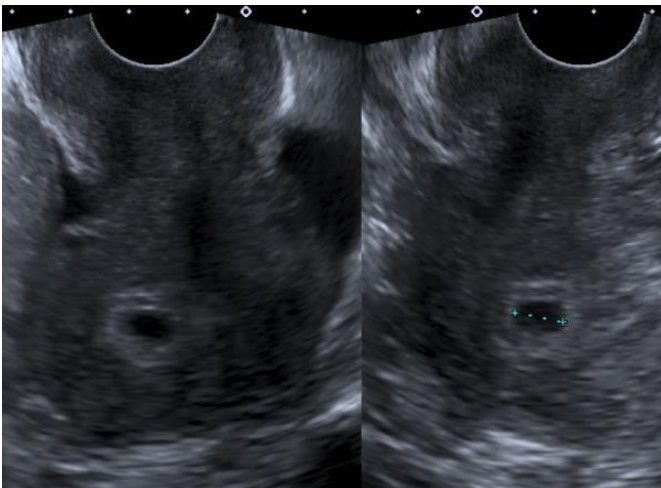


Fig 2: Early intrauterine gestational sac

Case 2

A 24-year-old, prim gravida, attended at 7 weeks of gestation with right iliac fossa pain and minimal PV bleeding. She had chlamydia in the past. 3 β -hCGs done at 48 hour intervals showed plateauing levels - 3841 IU/L, 4425 IU/L, 4585 IU/L. Progesterone levels were not done. A Departmental scan showed findings as in (Figure 3).

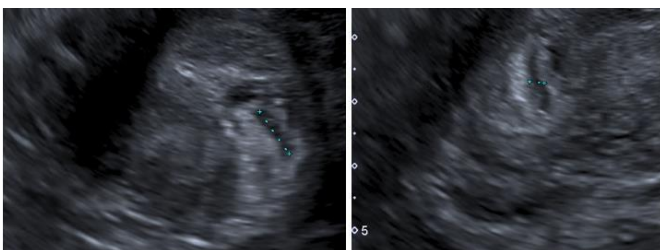


Fig 3: Endometrial thickness (ET)=13.9 mm. Echoluscent area at fundus 5.4 mm. No adnexal masses

Examination revealed a soft abdomen with mild tenderness in right iliac fossa with no signs of acute abdomen. Possible differential diagnosis of ectopic pregnancy or missed

miscarriage was discussed with her. She was given the option of Laparoscopy +/- salpingectomy +/- surgical evacuation or to wait and have a repeat scan +/- methotrexate. Patient was keen to proceed with laparoscopy, which showed normal findings with no evidence of ectopic pregnancy and surgical evacuation performed in the same sitting showed products of conception confirmed on histology.

Case 3

A 22 year old para0+1, with previous ectopic treated with methotrexate, presented with lower abdominal pain on right side and no PV bleed. Examination findings were unremarkable. Scan findings were as shown in (Figure 4).

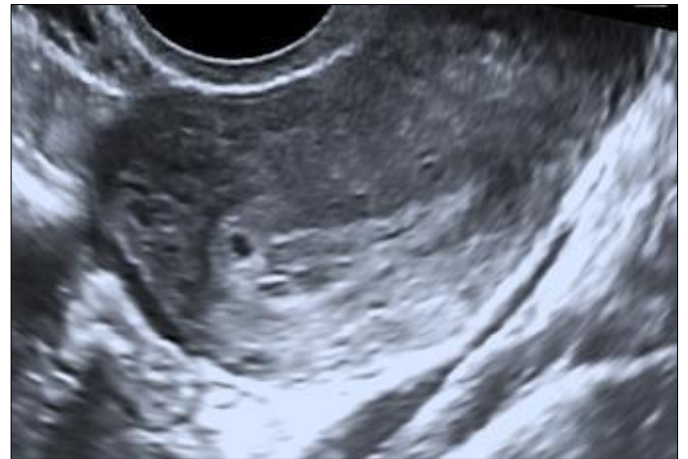


Fig 4: ET=9.7 mm. Rounded fluid area 3.2 mm towards fundus? Early gestation. No yolk sac. Both ovaries normal

Her biochemical markers showed an initial β -hCG level 668 IU/L, 48 hours β -hCG 740 IU/L, progesterone level 10.7nmol/L. She represented on third day with increasing pain, vomiting and diarrhoea. Examination showed tenderness all over the abdomen with no guarding or rigidity. A repeat scan showed following findings (Figure 5).

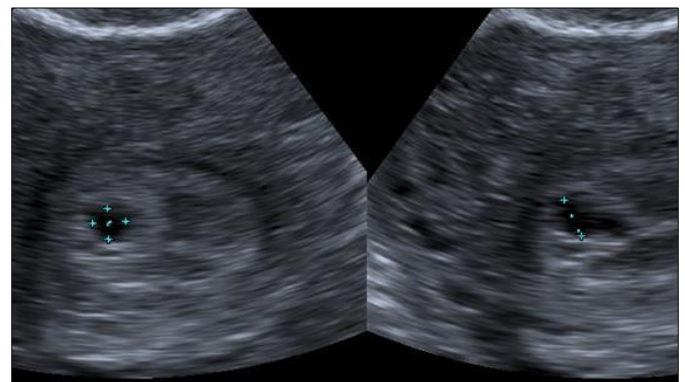


Fig 5: ET=10 mm. cystic area 2.6 mm. No adnexal masses and trace of fluid adjacent to left Ovar

A repeat β -hCG on the day showed a level of 765 IU/L. Possibility of failing pregnancy (either ectopic or early intrauterine pregnancy failure) was discussed with her. She was given the option of laparoscopy v/s methotrexate. She was keen to proceed with laparoscopy which showed normal findings. Surgical evacuation performed in the same sitting showed minimal products confirmed on histology. Repeat β -hCG 48 hours after the procedure showed a declining trend with a level of 125 IU/L and was negative (8 IU/L) after 1 week.

Discussion

Laparoscopy in ectopic pregnancy is used in cases where surgical intervention is thought to be urgent as in clinically unstable patient or for treatment in a stable patient who doesn't satisfy the criteria for expectant or medical management. It is no longer the 'gold standard' diagnostic test and is replaced by transvaginal ultrasound (TVS) with reported sensitivities of 87.0–99.0% and specificities of 94.0–99.9% with an initial TVS picking up to 73.9% of women with ectopic pregnancy.³ Due to this, about 94% of ectopic pregnancies are diagnosed prior to surgical intervention^[4]. Tubal ectopic pregnancies could be visualised on TVS as an inhomogeneous or adnexal mass (Blob sign 50–60%) or empty extra uterine gestational sac (Bagel sign 10–20%) or an extra uterine gestational sac with yolk sac and/or embryonic pole with or without cardiac activity (15–20%)^[5].

Where ectopic pregnancy is not positively identified as an adnexal mass separate to ovary and there is no definite evidence of intrauterine pregnancy are classed as pregnancies of unknown location (PUL). Not all clinicians are trained in early pregnancy scans which inevitably leads us to rely on the reports given by the sonographers. Difficulty arises when it is not easy to differentiate between an early intrauterine gestational sac and a pseudo sac. A pseudo sac is a collection of fluid in the endometrial cavity which is seen in about 20% cases of ectopic pregnancy^[6]. There is no specific endometrial appearance or thickness to support a diagnosis of tubal ectopic pregnancy. Presence of an intrauterine smooth walled anechoic cystic structure and no adnexal mass has a probability of ectopic pregnancy of 0.02% and probability of 99.98% of an intrauterine pregnancy^[7]. An early intrauterine pregnancy sac may be diagnosed by intradecidual (fluid collection with an echogenic rim located within a markedly thickened decidua on one side of the uterine cavity)^[8] and double decidual signs (an intrauterine fluid collection surrounded by two concentric echogenic rings)^[9]. This was probably the dilemma in cases 2 and 3 for attending clinicians. If the ultrasound report doesn't give a definite indication of possible early intrauterine gestational sac, in the absence of experience in scanning, one would have to rely on other parameters like biochemical markers and clinical presentation of patient. Serum Bhcg has been a useful marker in managing ectopic pregnancies. A rise of β -hCG between 50% and 66% in 48 hours is considered acceptable in a normal pregnancy^[10] and absence of this expected rise suggests early pregnancy failure. Majority of ectopic pregnancies will have suboptimal rise or fall with no single pattern able to characterise the condition, with about 15–20% showing rise similar to intrauterine pregnancy and about 10% behaving like failing PUL^[4].

In cases 2 and 3, β -hCG levels showed suboptimal rise in levels which indicated a failing pregnancy. In our view, it would be a good practise to review scan pictures or discuss the findings with sonographers or colleagues experienced in scanning. This however may not be very easy with increasing day to day workload. Both these patients were consented for surgical evacuation as possibility of failing intrauterine pregnancy was considered. However, the clinician probably didn't want to miss a diagnosis of ectopic pregnancy which is again understandable in this era of high litigation.

The other biochemical marker is serum progesterone level which is a good indicator of early pregnancy viability but a poor predictor of location. Serum progesterone level above 60 nmol/L is strongly associated with an intrauterine pregnancy. Levels below 20 nmol/L have a high positive predictive value for failing pregnancies^[11]. In case 2, progesterone levels were not

done but were on the lower side in case 3 suggesting a failing pregnancy. In case 1, the levels were high which showed a possibility of a viable pregnancy (intrauterine or live ectopic). But the clinical presentation warranted a look with laparoscopy. Though most ectopic pregnancies present with varying amount of pain and bleeding, upto 10% remain asymptomatic with few presenting with nonspecific symptoms difficult to differentiate from other gynaecological conditions (eg corpus luteum cyst rupture, adnexal torsion, salpingitis), gastrointestinal and urological disorders (appendicitis, UTI)^[12]. Recent MMBRACE report has stressed the importance of considering diagnosis of ectopic pregnancy in any woman presenting to emergency department with collapse, acute abdominal/pelvic pain or gastrointestinal symptoms, particularly diarrhoea, vomiting and dizziness. All 3 patients were clinically stable though the third one did present with symptoms of diarrhoea and vomiting and her past history of ectopic could influence decision making.

In case 1, patient presented with pain and an adnexal mass was visualised along with free fluid in the pelvis which indicated a laparoscopy. However in retrospect, the presence of fluid could have been due to rupture of a corpus luteum cyst. Progesterone level was high 60 nmol/L but this can possibly happen even with a viable ectopic pregnancy. A small amount of anechoic free fluid in the pouch of Douglas may be found in both intrauterine and ectopic pregnancies. But it becomes significant if it is moderate to severe amount or echogenic signifying a tubal rupture. Atri *et al.*^[13] have suggested a model with three criteria which may predict massive haemoperitoneum in ectopic pregnancy: moderate to severe spontaneous pelvic pain, fluid above the uterine fundus or around the ovary at ultrasound, and low serum haemoglobin concentration of <10 g/L.

Patient's wishes, her clinical condition, scan picture, biochemical markers need to be taken into account when deciding on management of a suspected ectopic pregnancy when diagnosis is not clear. It is possible that laparoscopy may have been averted in cases 2 and 3, had there been, a clinician experienced in scanning and managing early pregnancy problems. There was a possibility that these patients would have been exposed unnecessarily to the effects of methotrexate had they accepted it as an option as both these pregnancies turned out to be intrauterine rather than ectopic pregnancies. False-negative laparoscopies (3.0 – 4.5%) have been reported when the procedure is performed too early in the development of an ongoing ectopic pregnancy. Though commonly performed, laparoscopy does need training in developing skills and competency and experience in dealing with complications. One maternal death was reported in the recent MMBRACE report 205-17 due to complication of laparoscopy. It should only be performed when surgical intervention is indicated as it would expose the patient to unnecessary surgical intervention.

Conclusion

Would we be justified in doing laparoscopy for diagnosis of ectopic pregnancy in this era of excellent transvaginal scanning? Each procedure should be justified based on the whole clinical and biochemical picture and experience of clinician giving paramount importance to patient safety, which should be at the heart of every clinical decision.

References

1. Diagnosis and management of ectopic pregnancy: RCOG Green Top Guideline No 21: Published 04/11/2016
2. Saving Lives, Improving Mothers' care: MMBRACE –UK, 2015-2017.

3. Emma Kirk, Aris T. Papageorghiou, George Condous, Linda Tan, Shabana Bora, Tom Bourne. The diagnostic effectiveness of an initial transvaginal scan in detecting ectopic pregnancy. *Human Reproduction*. 2007; 22:2824–2828.
4. Kirk E, Bottomley C, Bourne T. Diagnosing ectopic pregnancy and current concepts in the management of pregnancy of unknown location. *Human Reproduction Update*. 2014; 20(2):250–261.
5. Condous G, Okaro E, Khalid A, Lu C, Van Huffel S, Timmerman D *et al*. The accuracy of transvaginal ultrasonography for the diagnosis of ectopic pregnancy prior to surgery. *Hum Reprod*. 2005; 20:1404–9.
6. Benson CB, Doubilet PM, Peters HE, Frates MC. Intrauterine fluid with ectopic pregnancy: a reappraisal. *J Ultrasound Med*. 2013; 32:389–93.
7. Doubilet PM, Benson CB. Double sac sign and intradecidual sign in early pregnancy: interobserver reliability and frequency of occurrence. *J Ultrasound Med*. 2013; 32:1207–14.
8. Yeh HC, Goodman JD, Carr L, Rabinowitz JG. Intradecidual sign: a US criterion of early intrauterine pregnancy. *Radiology*. 1986; 161:463–7.
9. Bradley WG, Fiske CE, Filly RA. The double sac sign of early intrauterine pregnancy: use in exclusion of ectopic pregnancy. *Radiology*. 1982; 143:223–6.
10. Horne AW, McBride R, Denison FC. Normally rising hCG doesn't predict live birth in women presenting with pain and bleeding in early pregnancy. *Eur J Obstet Gynecol Reprod Biol*. 2011; 156:120-121.
11. Banerjee S, Aslam N, Woelfer B, Lawrence A, Elson J, Jurkovic D. Expectant management of early pregnancies of unknown location: a prospective evaluation of methods to predict spontaneous resolution of pregnancy *BJOG*. 2001; 108:158-163.
12. Vanitha N Sivalingam, Colin Duncan W, Emma Kirk, Lucy A Shephard, Andrew W Horne. Diagnosis and management of ectopic pregnancy. *J Fam Plann Reprod Health Care*. 2011; 37(4):231–240.
13. Atri M, Leduc C, Gillett P, Bret PM, Reinhold C, Kintzen G *et al*. Role of endovaginal sonography in the diagnosis and management of ectopic pregnancy. *Radiographics*. 1996; 16:755–74.
14. Dr. Manzura R Mulani, Dr. Pandharinath S Gawali, Dr. Veena S Hatolkar. Study of biochemical markers in patients of ischemic heart disease and hypertension in IIMSR Hospital, Warudi. *Int J Adv Biochem Res* 2019;3(2):05-08. DOI: 10.33545/26174693.2019.v3.i2a.33.