

# International Journal of Clinical Obstetrics and Gynaecology

ISSN (P): 2522-6614  
ISSN (E): 2522-6622  
© Gynaecology Journal  
[www.gynaecologyjournal.com](http://www.gynaecologyjournal.com)  
2020; 4(4): 68-70  
Received: 05-05-2020  
Accepted: 07-06-2020

**Dr. Qazi Jaweria Amber**  
MBBS, DGO, DNB, FMAS  
Fellow in Minimal Access,  
Gynecological Surgeries Grant  
Medical College and JJ group of  
Hospital, Mumbai, and  
Maharashtra, India

**Dr. Tushar Tatyaba Palve**  
MBBS, Associate Professor and  
Unit Head, MS Obstetrics and  
Gynecology, Grant Medical College  
and JJ Group of Hospital,  
Mumbai, Maharashtra, India

**Corresponding Author:**  
**Dr. Qazi Jaweria Amber**  
MBBS, DGO, DNB, FMAS  
Fellow in Minimal Access,  
Gynecological Surgeries Grant  
Medical College and JJ group of  
Hospital, Mumbai, and  
Maharashtra, India

## Laparoscopic management of benign ovarian cysts at tertiary care centre

**Dr. Qazi Jaweria Amber and Dr. Tushar Tatyaba Palve**

**DOI:** <https://doi.org/10.33545/gynae.2020.v4.i4b.622>

### Abstract

**Background:** This study was undertaken to assess the feasibility and outcome of laparoscopic surgery for the management of ovarian cysts at tertiary care centre.

**Methods:** Twelve patients from September 2018 to July 2019 presenting to our centre Cama And Albeless Hospital, Grant Medical College and JJ group of Hospital presumed to be benign ovarian cyst either on ultrasonography or clinical examination were managed laparoscopically. One case out of the above 12 cases came out as an incidental finding during diagnostic laparoscopy was also managed endoscopically. Preliminary evaluation suggestive to be of benign ovarian cyst by history, clinical examination, sonographic imaging and basic serum marker were only included in this study. The cysts were aspirated initially followed by cystectomy, oophorectomy or total hysterectomy depending on age, parity, coexisting pathology and desire for future fertility.

**Results:** Pain in abdomen was the most common presenting symptom of patient in our study. We were able to manage 84 % of patient with laparoscopy with laparotomy required for just 2 out of 12 cases. Serous cyst adenoma (25%) endometrioma (25%) were the most common findings on histopathology.

**Conclusions:** With proper patient selection and exclusion of malignancy, laparoscopic management of ovarian cyst by is feasible.

**Keywords:** Benign ovarian cysts, Laparoscopy, laparoscopic ovarian cystectomy.

### Introduction

Today's era there is more demand for a surgical treatment which is more conservative and less invasive. Thus, Operative laparoscopy is now being more preferred for surgical management of gynaecological condition particularly benign etiology.

As compared to open technique laparoscopic surgery has multiple advantage like minimal incisions hence more cosmetic, reduced post-operative pain, short hospital stay, early ambulation, early resumption of normal activities and reduced chance of deep venous thrombosis and pulmonary embolism, fewer complications related to the incision overall better patients' satisfaction and post-operative quality of life. However the visualization of the operative field, surgical outcome and the ability to achieve the surgical objectives have been similar among patients undergoing laparoscopic surgery compared to those whose surgery was performed through laparotomy.

Adnexal masses both benign and malignant is a very common presentation amongst all age women presenting to gynaecology Out Patient Department. Up to 10% of women will have some form of surgery during their lifetime for the presence of an ovarian mass [1]. Recent advances in endoscopic surgical techniques have offered new possibilities for laparoscopic treatment of large ovarian cysts [2].

Most of these ovarian neoplasms are benign and the overall incidence of asymptomatic ovarian cyst in a premenopausal female being malignant is only approximately 1:1000 increasing to 3:1000 at the age of 50. Ovarian cysts are common in postmenopausal women. The exact prevalence is unknown given the limited amount of published data and the lack of established screening programmes for ovarian cancer [3] However, studies [4] have estimated the incidence to be anywhere between 5% and 17%. The vast majority of these identified cysts are benign. Therefore, the underlying management rationale is to distinguish between those cysts that are benign and those that are potentially malignant. This will help in deciding further management in terms of conservative or radical management. The morbidity and outcomes can be improved by [5, 6] using conservative management where possible the use of laparoscopic techniques where

appropriate, thus avoiding laparotomy where possible referral to a gynaecological oncologist when appropriate. [7]. However these days with the recent advances and trained operating surgeons even malignant procedures can be managed laproscopically.

### Methods

All women presenting with benign adnexal mass on ultrasonography and routine tumor marker screening during September 2018 to July 2019 (11 months) to our tertiary care centre and teaching Institution was considered for this study. Pre-operative evaluation included history, clinical examination, ultrasound examination and basic serum marker evaluation (CA-125 upper limit 35U/ml).

### Inclusion criteria

It included ovarian cyst with low probability of malignancy. Cases with ascites, solid/complex mass, enlarged lymph nodes, elevated CA -125 were excluded from study.

Written informed consent was obtained from the patients after a thorough counselling, detailing therapeutic options, risks of the procedure, and the need for possible laparotomy or other indicated procedures. All procedures were performed by surgeons with training and experience in laparoscopic procedures.

10 mm primary port accessed supraumbilically in all cases either by open laparoscopy or by creating pneumoperitonium depending on the case. Three 5 mm working ports created, one on both side an inch above and medial to superior iliac spine, third port on left side midway between primary port and 5mm port. The cyst wall, interior of the capsule and the visceral organs were examined systematically for any suspicious signs of malignancy.

The cysts were aspirated initially followed by cystectomy, oophorectomy or total hysterectomy depending on age, parity,

coexisting pathology and desire for future fertility. In cystectomy, capsule stripped from remaining ovarian tissue using graspers and bipolar current was used to coagulate the bleeding surface. If cystectomy was not performed or was not feasible, then cystic ovary (along with saplings in some cases) was mobilized and separated from its attachments using bipolar coagulation and cold scissors. If associated with other uterine pathology, sapling oophorectomy followed by hysterectomy performed and the entire specimen was delivered vaginally. Specimen was retrieved by either of the 2 methods.

- Enmass along with cannula-through 10 mm primary port held with grasper,
- In bits and pieces-through 10 mm port after cutting into small strips or

We resorted to mini laparotomy, if all the above method fails. After the tissue was removed, the abdominal and pelvic cavities were thoroughly irrigated with copious amounts of normal saline. All the patients were discharged on 2nd or 3<sup>rd</sup> post-operative day with standards of care at our institution.

### Observation and Discussion

**Table 1:** Symptoms of patients with ovarian cyst.

| Symptoms                 | Number of patients | Percentage |
|--------------------------|--------------------|------------|
| Pain in abdomen          | 5                  | 41%        |
| Infertility              | 4                  | 33%        |
| Menstrual Irregularities | 2                  | 16%        |
| Abdominal distension     | 2                  | 16%        |
| Incidental finding       | 1                  | 8%         |

Patient usually presented with pain in abdomen as a most common finding. However some of them usually presented with multiple symptoms like pain in abdomen with infertility or pain in abdomen with menstrual irregularities.

**Table 2:** Laparoscopic procedure done.

| Procedure   | Number of patients | Percentage |
|---|--------------------|------------|
| Laparoscopic cystectomy                           | 6                  | 50%        |
| Laparoscopic oophorectomy/salpingo-oophorectomy   | 0                  | 0%         |
| Laprosopic cyst aspiration                        | 3                  | 25%        |
| Laparoscopic adnexectomy followed by hysterectomy | 1                  | 8%         |
| Laparoscopy followed by Laparotomy (conversion)   | 2                  | 16%        |

Most of the cases could be completed laparoscopically (84%) without any complication and conversion to laparotomy was needed in 2 cases (9.3%) to achieve desired surgical outcome (1 cases of severe endometriosis, 1 of large dermoid cyst to prevent spillage of irritable contents). Patients underwent cystectomy, or total hysterectomy depending on age, parity, desire for future fertility and operative feasibility. Three patients with ultrasonography suggestive of simple cyst with normal tumor marker presenting as pain in abdomen with large cyst, cyst aspiration was done and fluid send for cytology. Of them one cyst had chocolate fluid during aspiration. One case presenting as DUB with prolapse was managed with lap adnexectomy with total laparoscopic hysterectomy.

**Table 3:** Histopathology of specimen.

| Histopathology           | Number of patients | Percentage |
|--------------------------|--------------------|------------|
| Serous cyst adenoma      | 3                  | 25%        |
| Mucinous cystadenoma     | 0                  | 00%        |
| Seromucinous cystadenoma | 2                  | 16%        |
| Dermoid                  | 2                  | 16%        |
| Endometrioma             | 3                  | 25%        |
| Benign cystic aspirate   | 2                  | 16%        |

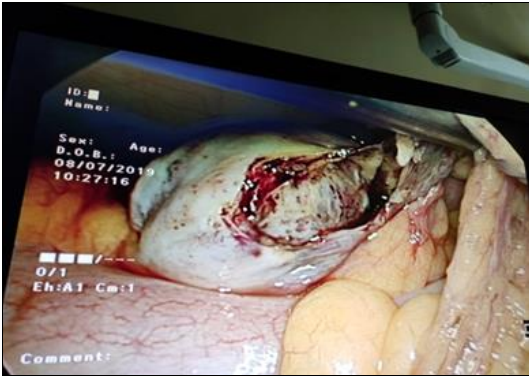
Three cases were serous cyst adenoma with 2 cases given diagnosis as fibro collagenous cyst lined by cuboidal to mucin secreting columnar Seromucinous cystadenoma, 2 cases as evident even on laproscopy were mature teratoma on histopathology and remaining 3 cases being endometrioma.

### Results

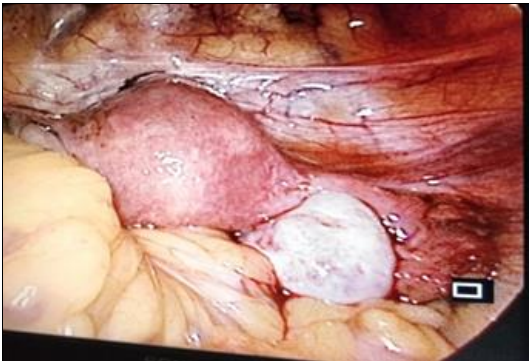
Out of 12 cases, 5 presented as pain in abdomen as most common symptom. 11 out of 12 cases were prediagnosed on clinical examination ultrasonography while one case was an incidental finding in a case of diagnostic laproscopy in case of infertility which was managed with laproscopic cystectomy and was endometrioma on histopathology. Most of women were successfully treated laproscopically without any complications and conversion to laparotomy was required in 2 cases. Serous cystadenoma and endometrioma were the most common finding accounting for 50% (25% each) with dermoid (16%) in of cases.

### Conclusion

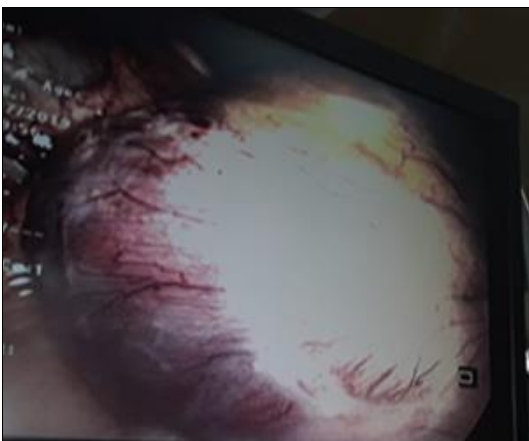With proper selection of cases and available resources laproscopy can a better and feasible management option for benign ovarian masses particularly in today's era with high demand for conservative surgeries.



**Fig 1:** Laparoscopic management of Endometriotic cyst



**Fig 2:** Lap management of dermoid



**Fig 3:** Laparoscopic management of Simple Ovarian Cyst

## References

1. Management of Suspected Ovarian Masses in Premenopausal Women. Green-top Guideline No. 62 RCOG/BSGE Joint Guideline I, 2011, 2.
2. Yuen PM, Yu KM, Yip SK, Lau WC, Rogers MS CA. A randomized prospective study of laparoscopy and laparotomy in the management of benign ovarian masses. *Am J Obs Gynecol*, 1997, 177(109-14).
3. Dørum A, Blom GP, Ekerhovd E GS. Prevalence and histologic diagnosis of adnexal cysts in postmenopausal women: an autopsy study. *Am J Obs Gynecol*. 2005; 192(48):54.
4. Greenlee RT, Kessel B, Williams CR, Riley TL, Ragard LR, Hartge P *et al*. Prevalence, incidence, and natural history of simple ovarian cysts among women >55 years old in a large cancer screening trial. *Am J Obs Gynecol*. 2010; 202:373.
5. Canis M, Botchorishvili R, Manhes H, Wattiez A, Mage G,

Pouly JL *et al*. Management of adnexal masses: role and risk of laparoscopy. *Semin Surg Oncol*. 2000; 19(28):35.

6. Quinlan DJ, Townsend DE JG. Safe and cost-effective laparoscopic removal of adnexal masses. *Am Assoc Gynecol*. 1997; 4(215):18.
7. GGN. The Management of Ovarian Cysts in Postmenopausal Women, 34.