

International Journal of Clinical Obstetrics and Gynaecology

ISSN (P): 2522-6614
ISSN (E): 2522-6622
© Gynaecology Journal
www.gynaecologyjournal.com
2018; 2(3): 30-33
Received: 08-03-2018
Accepted: 09-04-2018

Shruthi A

Junior Resident, College-ESIC
Medical College and PGIMSR,
Bangalore University- Rajiv
Gandhi University of Health
Sciences Department- OBG,
Karnataka, India

Sreelatha S

Professor, College- ESIC Medical
College and PGIMSR, Bangalore,
University- Rajiv Gandhi
University of Health Sciences,
Department- OBG, Karnataka,
India

Satish Kumar

Junior Resident, College- ESIC
Medical College and PGIMSR,
Bangalore, University- Rajiv
Gandhi University of Health
Sciences, Department- OBG,
Karnataka, India

Kavitha BL

Junior Resident, College- ESIC
medical college and PGIMSR,
Bangalore, university- Rajiv
Gandhi University of health
sciences, department- OBG,
Karnataka, India

Correspondence

Shruthi A

Junior Resident, College-ESIC
medical college and PGIMSR,
Bangalore university- Rajiv
Gandhi University of health
sciences department- OBG,
Karnataka, India

Adenomyosis in patients undergoing hysterectomy for leiomyomas: A retrospective study

Shruthi A, Sreelatha S, Satish Kumar and Kavitha BL

Abstract

Aim: To identify the prevalence of Adenomyosis in patients who underwent hysterectomy for fibroid uterus, and to correlate patient profile, clinical finding and reproductive characteristics.

Methodology: This is a retrospective study conducted at ESIC Medical College and PGIMSR, Rajajinagar Bangalore. Women who underwent abdominal or vaginal hysterectomy for proven uterine leiomyomas on ultrasonography with or without oophorectomy in a 3 year period from 2013 to 2016 were included in the study. Retrospectively data was collected from medical records regarding age, parity, presenting symptoms, histopathological report of hysterectomy specimen for evidence of concurrent adenomyosis. Statistical analysis of data was carried out using SPSS statistical software. Quantitative data were analysed with mean, median and standard deviation. Qualitative data (categorical) were analysed with percentages and frequencies.

Results: We had 180 patients who underwent hysterectomy with or without oophorectomy for fibroid uterus in our study period. Out of which 108(60%) patients were found to have adenomyosis. Adenomyosis was more commonly seen in patients with older age group than with patients with fibroid alone. The patients with concurrent adenomyosis significantly presented with dysmenorrhoea (P-0.001) and pelvic pain (P-<0.001), also the size of the uterus at the time of surgery was less than 12week in a significant population (P-0.243). Reproductive data between the two cohort, showed that significant patients with leiomyomas alone were nulliparous (P-0.015) and as parity increased to two or more the patients were prone to have concurrent Adenomyosis (P-0.008).

Conclusion: Our study shows that 60% of patients who underwent hysterectomy for fibroid uterus had concurrent Adenomyosis. Patients with concurrent Adenomyosis more frequently presented with Dysmenorrhoea and pelvic pain than with patients with fibroid alone. As the parity increased the risk of having co existing adenomyosis also increased significantly. A detail history obtained from the patients with reproductive history along with use of modern non-invasive diagnostic imaging modality like transvaginal ultrasonography, magnetic resonance imaging and nuclear magnetic resonance can aid in the diagnosis of Adenomyosis in patients prior to hysterectomy.

Keywords: Leiomyomas, Adenomyosis, hysterectomy, dysmenorrhoea, pelvic pain, histopathology

Introduction

Adenomyosis is a benign uterine condition characterized by the presence of endometrial glands and stroma deep in the myometrium. This haphazard location of endometrium deep in the myometrium should be atleast 2.5mm below the endomyometrial junction for the diagnosis of Adenomyosis [1]. Leiomyomas on the other hand are also benign myometrial neoplasms. These are monoclonal tumors of the smooth muscle cells of the myometrium and consists of large amounts of extracellular matrix that contains collagen, fibronectin, proteoglycans and surrounded by a pseudocapsule composed of areolar tissue and compressed muscle fibers [2].

The main symptoms caused by Adenomyosis include abnormal uterine bleeding, dysmenorrhoea, chronic pelvic pain and dyspareunia [3]. And those caused by Fibroids include heavy menstrual cycles, mass per abdomen, pressure symptoms with bowel and bladder symptoms and dysmenorrhoea. Since both these conditions often co-exist in the same uterus, most of the times it is difficult to attribute the symptom to either condition alone and overlap each other in most cases [4].

Although the two conditions co exists the treatment option vary widely depending on the predominant condition and the presenting symptom. Fibroids are usually dealt with hysterectomy or myomectomy although medical line of treatment include oral contraceptive, progestogens: oral or Intra Uterine Device and recently with nonsurgical alternatives such as Uterine artery embolization and fibroid ablation [5].

The treatment options available for adenomyosis is limited due to its delayed diagnosis often after hysterectomy retrospectively. Conservative management with progestogens, endomyometrial ablation, laparoscopic myometrial electrocoagulation or excision is effective in >50% of cases and hysterectomy is needed in only deep seated adenomyosis [6].

Adenomyosis was found concomitantly in hysterectomy specimens of those undertaken for fibroid uterus with an incidence of 15-57% [7]. Often the diagnosis of Adenomyosis was made retrospectively from histopathological examination of hysterectomy specimen rather than pre operatively. This under diagnosis of Adenomyosis is one of the reasons of treatment failure and increased hysterectomy rates in patients with fibroid uterus. Thus this study aims to identify the prevalence of Adenomyosis in patents who underwent hysterectomy for fibroid uterus, and to correlate their clinical finding and reproductive characteristics to allow better clinical decision making regarding alternative to hysterectomy and decrease the risk of treatment failure.

Methodology

This is a retrospective study conducted at ESIC Medical College and PGIMSR, Rajajinagar Bangalore. Women who underwent abdominal or vaginal hysterectomy for proven uterine leiomyomas on ultrasonography with or without oophorectomy in a 3 year period from 2013 to 2016 were included in the study.

Retrospectively data was collected from medical records regarding age, parity, presenting symptoms, histopathological report of hysterectomy specimen for evidence of concurrent adenomyosis. Adenomyosis was diagnosis when the distance between the lower border of the endometrium and the affected myometrial area was over one-half of a low power field (2.5mm). The patients in whom hysterectomy was performed for Adenomyosis alone were excluded from the study.

Statistical analysis of data was carried out using SPSS statistical software. Quantative data were analysed with mean, median and standard deviation. Qualitative data (categorical) were analysed with percentages and frequencies. The significance in difference between the two groups were assessed with cross tables, Pearson’s chi square test and Fishers exact test were applied where ever necessary.

Results

We had 180 patients who underwent hysterectomy with or without oophorectomy for fibroid uterus in our study period. Out of which 108(60%) patients were found to have adenomyosis identified in histopathological report after hysterectomy. The patents were divided into 2 cohort depending on presence or absence of concurrent adenomyosis and retrospective analysis was carried out. The mean age of patients with leiomyoma alone was 43(SD- 4.2) years and those of leiomyoma and adenomyosis was 45(SD- 4.5) years.

Table 1: Clinical symptoms and uterine size of the cohort

	Leiomyoma n(%)	Leiomyoma with Adenomyosis n(%)	P ^{a/b} (significance)
1. Menorrhagia/metrorrhagia	23(31.9)	30(27.8)	0.548(NS) ^a
2. Dysmenorrhoea	27(37.5)	68(63.0)	0.001(S) ^a
3. Pelvic pain	13(18.1)	47(43.5)	<0.001(S) ^a
4. Uterus size >12weeks	27(37.5)	50(46.3)	0.243(S) ^a
5. Pressure symptoms	12(16.7)	2(1.9)	<0.001(S) ^a
6. Dyspareunia	3(4.2)	5(4.6)	1.000(NS) ^b

P^a- Pearson’s chi square test. A P value of <0.005 was considered statistically significant difference.

P^b- Fishers test

S- Significant statistically.

NS- Not Significant statistically.

The patients records were analysed for presenting symptoms, and we found that patients with concurrent adenomyosis significantly presented with dysmenorrhoea (P-0.001) and pelvic pain (P-<0.001). The size of the uterus at the time of surgery was less than 12week in a significant population (P-0.243) indirectly indicating that the patients presented early to the clinic because of the distressing symptoms and surgery was

undertaken because of symptomatic fibroid. [Table-1]
The patients with fibroid alone presented more with a pressure symptoms (P-<0.001) and the size of uterus was more than 12 weeks in a significant population. However no difference was see regarding symptoms like menorrhagia, metrorrhagia and dyspareunia. [Table-1]

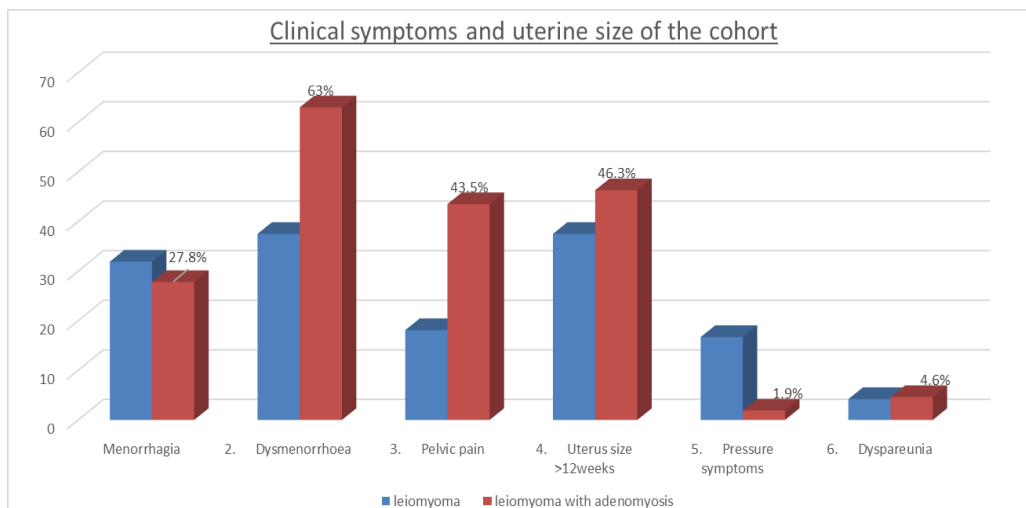


Table 2: Reproductive characteristics of the 2 cohort

	Leiomyoma n(%)	Leiomyoma with Adenomyosis n(%)	P ^a
1. Nulliparity	13(18.1)	07(6.5)	0.015(S) ^a
2. Parity >or= 2	38(52.8)	78(72.2)	0.008(S) ^a
3. Spontaneous/medical abortions	24(33.3)	35(29.6)	0.599(NS) ^a
4. Surgical abortions	6(8.3)	11(10.2)	0.677(NS) ^a
5. Caesarean / uterine scar	22(30.6)	29(26.9)	0.589(NS) ^a

P^a- chi square test of significance, a P value of <0.05 is considered statistically significant.

S- Significant statistically.

NS- Not Significant statistically.

From the analysis of reproductive data between the two cohort, we found that significant patients with leiomyomas alone were nulliparous (P-0.015) and as parity increased to two or more the patients were prone to have concurrent Adenomyosis (P-0.008). However significant difference were not found with the presence of spontaneous or surgical abortion nor the patients who underwent caesarean section or laparotomy with uterine scar with the occurrence of disease between the two cohort.

Discussion

In our current study we found the incidence of Adenomyosis in hysterectomy specimen performed in patients in view of fibroid uterus was about 60%. As our study is a retrospective study and based on histopathological report, the then pathologist reporting the specimen were unaware of the study. Thus there is a fair chance of the pathological condition to be over looked and the incidence being even more than what this study has concluded. This can be justified according to previous studies by Bird *et al.* which states that the possibility of demonstrating Adenomyosis on HPE is directly proportional to the pathologist awareness of the condition, the number and site of myometrial sample analysed [8].

Adenomyosis was more commonly seen in patients with older age group than with patients with fibroid alone and the size of the uterus was significantly less at the time of hysterectomy. These findings goes well with the previous study results by Taran FA *et al* in 2010 [7, 9]. This could be adenomyosis coexisting with small fibroids which were failed to be picked up on Transvaginal ultrasonography conducted pre operatively. The symptoms in such fibroids cases can be attributed to either Fibroids or adenomyosis. Thus by identifying such co existing adenomyosis with Magnetic resonance imaging and other recent imaging modalities, conservative line of management can be used with minimal treatment failure before planning hysterectomy.

The symptoms caused by adenomyosis and fibroids overlap each other making it difficult to attribute it to a single condition. However menorrhagia, dysmenorrhoea and chronic pelvic pain is significantly associated with adenomyosis and if present in a patient with fibroid uterus should alert the clinician to look for concurrent adenomyosis [9, 10]. This significance was also proven in our study. Although there was no significant difference in the occurrence of menorrhagia and dyspareunia between the two cohort in our study. Many other studies done previously also arrived at the same conclusion. A. Graziano *et al* also reported that 70% of patients with adenomyosis are symptomatic and mainly present with menorrhagia, dysmenorrhoea and chronic pelvic pain, while remaining 30% are asymptomatic [11].

On our analysis of obstetric history between the 2 cohorts. We found multiparous patients are more prone to develop concurrent adenomyosis. Pregnancy might facilitate adenomyotic foci to be included in myometrium during trophoblastic invasion of placenta [4, 12]. In addition hyper estrogen state during pregnancy

also facilitate development of islands of endometrium at ectopic sites including uterine myometrium [13]. Thus as the parity of the patients increase also does the risk of adenomyosis. Shretha *et al*, in their study also found a significant increase in adenomyosis as the parity increase [10].

We did not find a significant increase in concurrent adenomyosis with prior abortions (spontaneous/surgical) or Caesarean / uterine scar. Previously done studies however shows a rise in adenomyosis rate in patients who undergo dilatation and curettage, or previous disruption of endomyometrial-myometrial border from surgical incision on uterus as in Caesarean section [14, 15]. This deviation in our study may be because all caesarean were of lower segment with no incision involving upper segment (as in classical caesarean). A recent study done in 2012 by Taran FA *et al* also did not show a rise in adenomyosis in patients with prior uterine surgeries [7].

Thus this study reinforces the presence of distinct clinical features in patients of fibroid uterus with coexisting adenomyosis. A detail history obtained from the patients with reproductive history along with use of modern non-invasive diagnostic imaging modality like transvaginal ultrasonography, magnetic resonance imaging and nuclear magnetic resonance can aid in the diagnosis of Adenomyosis in patients prior to hysterectomy.

With early diagnosis of Adenomyosis, the disease can be managed with medial line alone or with conservative approach such as uterine artery embolization, endometrial ablation etc. Also by detection of concurrent adenomyosis in patients with smaller fibroid size, medical line of management and be exercised with minimal treatment failure and decrease the burden of surgery in such group of patients.

Conclusion

Our study shows that 60% of patients who underwent hysterectomy for fibroid uterus had concurrent Adenomyosis. Patients with concurrent Adenomyosis more frequently presented with Dysmenorrhoea and pelvic pain than with patients with fibroid alone. As the parity increased the risk of having co existing adenomyosis also increased significantly. A detail history obtained from the patients with reproductive history along with use of modern non-invasive diagnostic imaging modality like transvaginal ultrasonography, magnetic resonance imaging and nuclear magnetic resonance can aid in the diagnosis of Adenomyosis in patients prior to hysterectomy.

References

1. Azziz R. Adenomyosis: Current prespectives. *Obstet Gynecol Clin Nam.* 1989; 16:221-35.
2. Sankaran S, Manyonda IT. Medical management of fibroids. *Best Pract Res Clin Obstet Gynaecol.* 2008; 22(4):655-676.
3. Stewert EA. Uterine fibroids. *Lancet.* 2001; 357:293-298.
4. Weiss G, Maseelall P, Schott LL, Brockwell SE, Schocken

- M, Johnston JM. Adenomyosis a variant, not a disease? Evidence from hysterectomised menopausal women in the Study of Women's Health across the Nation (swan). *Fertil Steril*, 2009, 201-206.
5. Mas A, Tarazona M, Carrasco JD, Estaca G, Cristobal, Monleon J. Updated approaches for management of uterine fibroids. *International Journal of Women's Health*. 2017; 9:607-617.
 6. Wood C. Surgical and medical treatment of adenomyosis. *Human Reproduction Update*. 1998; 4(4):323-36.
 7. Taran FA, Wallwiener M, Kabashi D, Rothmund R, Rall K, Kraemer B *et al*. Clinical characteristics indicating adenomyosis at the time of hysterectomy: a retrospective study in 291 patients. *Archives of Gynecology and Obstetrics*. 2012; 285(6):1571-6.
 8. Bird CC, Mcelin TW, Manalo-Estrella P. The elusive adenomyosis of the uterus-revisited. *American Journal of Obstetrics and Gynecology*. 1972; 112(5):583-93.
 9. Taran FA, Weaver AL, Coddington CC, Stewart EA. Characteristics indicating adenomyosis coexisting with leiomyomas: a case-control study. *Human Reproduction*. 2010; 25(5):1177-82.
 10. Shrestha A, Shrestha R, Sedhai LB, Pandit U. Adenomyosis at hysterectomy: Prevalence, patient characteristics, clinical profile and histopathological findings. *Kathmandu Univ Med J*. 2012; 37(1):53-6.
 11. Graziano A, Lo Monte G, Piva I *et al*. Diagnostic findings in adenomyosis: a pictorial review on the major concerns. *Eur Rev Med Pharmac Sci*. 2015; 19(7):1146-1154.
 12. Templeman C, Marshall SF, Ursin G *et al*. Adenomyosis and Endometriosis in the California Teachers Study. *Fertil Steril*. 2008; 90:415-424.
 13. Vercellini P, Vigano P, Somigliana E *et al*. Adenomyosis: epidemiological factors. *Best Pract Res Clin Obstet Gynaecol*. 2006; 20:465-477.
 14. Levgur M, Abadi MA, Tucker A. Adenomyosis: symptoms, histology, and pregnancy terminations. *Obstet Gynecol*. 2000; 95:688-691.
 15. Panganamamula UR, Harmanli OH, Isik-Akbay EF *et al*. Is prior uterine surgery a risk factor of adenomyosis? *Obstet Gynecol*. 2004; 104:1034-1038.