

# International Journal of Clinical Obstetrics and Gynaecology

ISSN (P): 2522-6614  
ISSN (E): 2522-6622  
© Gynaecology Journal  
www.gynaecologyjournal.com  
2018; 2(3): 96-98  
Received: 25-03-2018  
Accepted: 27-04-2018

**Dr. Anshu Mishra**  
M. S. (Obs & Gynae), Professor,  
Govt. Medical College Kannauj,  
UP, India

**Dr. Meera Mathur**  
M. D. (Pathology), Associate Prof.  
Pathology, Govt. Medical College  
Kannauj, UP, India.

**Dr. Raghunath Singh**  
M. B. B. S., Junior Resident.  
Pathology, Govt. Medical College  
Kannauj, UP., India.

**Dr. Neha Kumari**  
M. B. B. S., J.R. Obs & Gynae.  
Govt Med. College Kannauj, UP,  
India..

## Risk factors of atypical hyperplasia of breast-Analysis of 156 cases

**Dr. Anshu Mishra, Dr. Meera Mathur, Dr. Raghunath Singh and Dr. Neha Kumari**

### Abstract

**Background:** Atypical hyperplasia of breast is benign lesion seen in females and requires early intervention to prevent complications. The present study was conducted to assess the risk factors associated with atypical hyperplasia of breast.

**Materials & Methods:** The present study was conducted on 156 cases of diagnosed atypical hyperplasia of breast. Type, family history and foci was evaluated in all cases. All histologic slides from biopsy specimens of women containing breast parenchyma were examined.

**Results:** Age group <40 years had 20 cases, 40-60 years had 60 and >60 years had 76 cases. The difference was significant (P<0.01). Types of hyperplasia were ductal hyperplasia (50), lobular hyperplasia (86) and ductal & lobular hyperplasia (20). The difference was significant (P<0.01). There was strong family history seen in 54 cases, weak in 30 cases and none in 72 cases. Foci of atypical hyperplasia was 1 (112), 2 (34) and 3 (10). The difference was significant (P<0.01).

**Conclusion:** Advanced age and family history are risk factors. Atypical hyperplasia of breast may be determined by biopsy of the lesion. This is useful in reaching the diagnosis.

**Keywords:** Atypical hyperplasia, breast, women

### Introduction

Atypical hyperplasia of breast is benign lesion seen in females and requires early intervention to prevent complications. Breast biopsies are commonly encountered to analyze mammographic or palpable findings that help in detection of lesions. About 1 million of the breast biopsies that are performed annually are found to be benign. On the basis of the histologic findings, it is possible to stratify women with benign biopsy findings into groups with significantly different risks of later breast cancer [1].

The precise anatomic definition of these lesions has been proposed only rarely, and their biologic or prognostic significance has never been rigorously studied. There is no definable borderline between carcinoma in situ and benign, while others have proposed a series of histologic steps between normal and malignant. There are two types of atypical hyperplasia ie atypical ductal hyperplasia and atypical lobular hyperplasia. Both carries equal frequency and similar risks of becoming breast cancer. Due to high incidence and high-risk features of atypical hyperplasia, management at early stages is of paramount importance [2].

Atypical hyperplasia of breast indicates the future outcome of the lesion. Biopsies are done at large scale in order to reach the diagnosis. Females with pain in breast, congestion and heaviness are required to consult gynaecologist. Higher female age and positive family history are among various risk factors [3]. Thus considering this, the present study was conducted to assess the risk factors associated with atypical hyperplasia of breast.

### Materials & Methods

The present study was conducted in the department of Obstetrics & Gynaecology. It comprised of 156 cases of diagnosed atypical hyperplasia of breast. All were informed regarding the study and written consent was obtained. Ethical clearance was obtained prior to the study from institutional ethical committee.

General information such as name, age, etc. was recorded. Type, family history and foci was evaluated in all cases. All histologic slides from biopsy specimens of women containing breast parenchyma examined. Results thus obtained were subjected to statistical analysis using chi-square test. P value less than 0.05 was considered significant.

### Correspondence

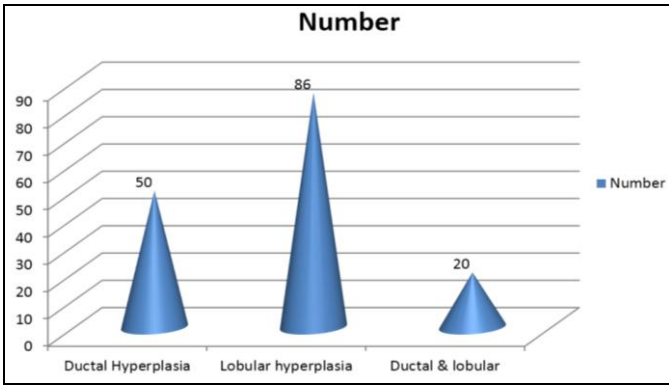
**Dr. Anshu Mishra**  
M. S. (Obs & Gynae), Professor,  
Govt. Medical College Kannauj,  
UP, India

**Results**

**Table 1:** Age wise distribution of cases

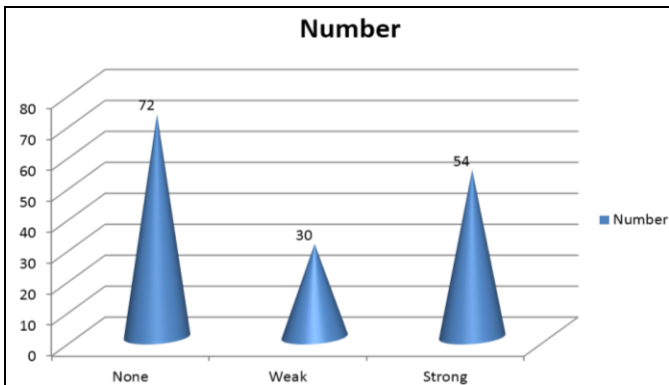
Age group	Number	P value
<40 years	20	0.01
40-60 years	60	
>60 years	76	
Total	156	

Table I shows that age group <40 years had 20 cases, 40- 60 years had 60 and >60 years had 76 cases. The difference was significant (P-0.01).



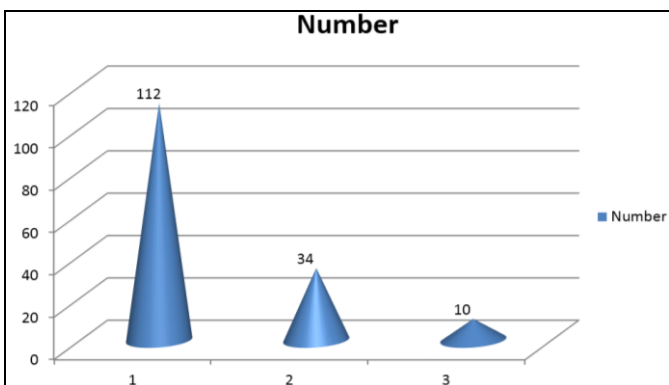
**Graph 1:** Type of atypical hyperplasia

Graph I shows that types of hyperplasia were ductal hyperplasia (50), lobular hyperplasia (86) and ductal & lobular hyperplasia (20). The difference was significant (P-0.01).



**Graph 2:** Family history of breast cancer

Graph II shows that there was strong family history seen in 54 cases, weak in 30 cases and none in 72 cases.



**Graph 3:** Foci of atypical hyperplasia

Graph III shows that foci of atypical hyperplasia was 1 (112), 2 (34) and 3 (10). The difference was significant (P-0.01).

**Discussion**

At the histologic borderline between carcinoma in situ and epithelial hyperplasia with no features of carcinoma in situ, there are lesions with some, but not all, of the features of carcinoma in situ. In this diagnostic gray zone, some use cytologic, histologic and/or quantitative features preferentially, leading to differences of opinion in diagnosis [4].

In present study, we included 156 cases of atypical hyperplasia of breast. We found that types of hyperplasia were ductal hyperplasia (50), lobular hyperplasia (86) and ductal & lobular hyperplasia (20). This is in agreement with Fisher *et al.* [5]

The younger a woman is when she receives a diagnosis of atypical hyperplasia, the more likely

It is that breast cancer will develop. The effect that a family history of breast cancer has on the breast-cancer risk among women with atypical hyperplasia has been controversial. Ackerman [6] described a subgroup of 39 women with atypical hyperplasia and a family history of breast cancer; these women had a relative risk of breast cancer of 8.9, as compared with a relative risk of 3.5.

We found that age group <40 years had 20 cases, 40-60 years had 60 and >60 years had 76 cases. Thus maximum cases were observed in age above 60 years of age. This is in agreement with Parl [7]. Current guidelines for breast-cancer screening of high-risk women, including guidelines from the NCCN, the American Cancer Society (ACS), and the American College of Radiology, focus primarily on women with hereditary risk. The ACS recommends annual breast MRI as an adjunct to mammography for high-risk patients who have a lifetime breast-cancer risk of approximately 20 to 25% or greater.

In this study, there was strong family history seen in 54 cases, weak in 30 cases and none in 72 cases. Foci of atypical hyperplasia were 1 seen in 112 cases, 2 in 34 cases and 3 in 10 cases.

David *et al.* [8] conducted a study and found that carcinoma in situ (CIS) was diagnosed in 1.7% of biopsy specimens. The subsequent risk of invasive breast carcinoma after ALH or ADH was 4-5 times that of the general population. History of breast cancer in a mother, sister, or daughter doubled the risk of subsequent invasive carcinoma development.

Surgical excision of the site of the atypical hyperplasia biopsy is recommended in the National Comprehensive Cancer Network (NCCN) guidelines. In the case of atypical ductal hyperplasia, the frequency of finding breast cancer with surgical excision is 15 to 30% or even higher, despite the use of large-gauge core-needle biopsy with vacuum assisted devices. Thus, excision remains the current standard when atypical ductal hyperplasia is identified by core biopsy [9]. However, studies are ongoing to identify situations in which surgical excision of atypical ductal hyperplasia may be avoided. In the case of atypical lobular hyperplasia, reported rates of upgrading have varied from 0 to 67%.

**Conclusion**

Atypical hyperplasia of breast may be determined by biopsy of the lesion. This is useful in reaching the diagnosis. Advanced age and family history are risk factors.

**References**

1. Haagensen CD, Lane N, Lattes R, Bodian C. Lobular neoplasia (so-called lobular carcinoma in situ) of the breast.

- Cancer, 1978, 42.
2. McDivitt RW, Stewart FW, Berg JW. Tumors of the breast. In: Atlas of Tumor Pathology, 2nd series, pt. 2. Armed Forces Institute of Pathology, 1968, 29-49.
  3. Rosen PP, Lieberman PH, Braun DW JI, Kosloff C, Adair F. Lobular carcinoma in situ of the breast: Detailed analysis of 99 patients with average follow-up of 24 years. Am J Surg Pathol. 1978; 2:225-51.
  4. Page DL, Dupont WD, Rogers LW, Landenberger M. Intraductal carcinoma of the breast: follow-up after biopsy only. Cancer. 1982; 49:751-58.
  5. Fisher ER. The pathology of breast cancer as it relates to its evolution, prognosis and treatment. Clin Oncol. 1982; 1:703-34.
  6. Ackerman LV, Katzenstein AL. The concept of minimal breast cancer and the pathologist's role in the diagnosis of early carcinoma. Cancer. 1977; 39:2755-63.
  7. Parl FF, Dupont WD. A retrospective cohort study of histologic risk factors in breast cancer patients. Cancer. 1982; 50:24, 10-24, 16.
  8. David. Proportional hazard regression models and the analysis of censored survival data. Applied Statistics. 1977; 26:227-237.
  9. Dixon JM, Anderson TJ, Lee D, Stewart HJ. Invasive cribriform carcinoma of the breast. Histopathology. 1983, 7525-536.